

Clinical Quiz

What is the Diagnosis?

MT **Soo**, SYR **LEE**, DKK **Ng**

Case History

A premature infant born at a gestational of 34 weeks was well at birth but presented with respiratory distress since 18 hours of life. He was intubated. Chest X-ray was taken and is shown.

Question

Name the radiological abnormality and the diagnosis?

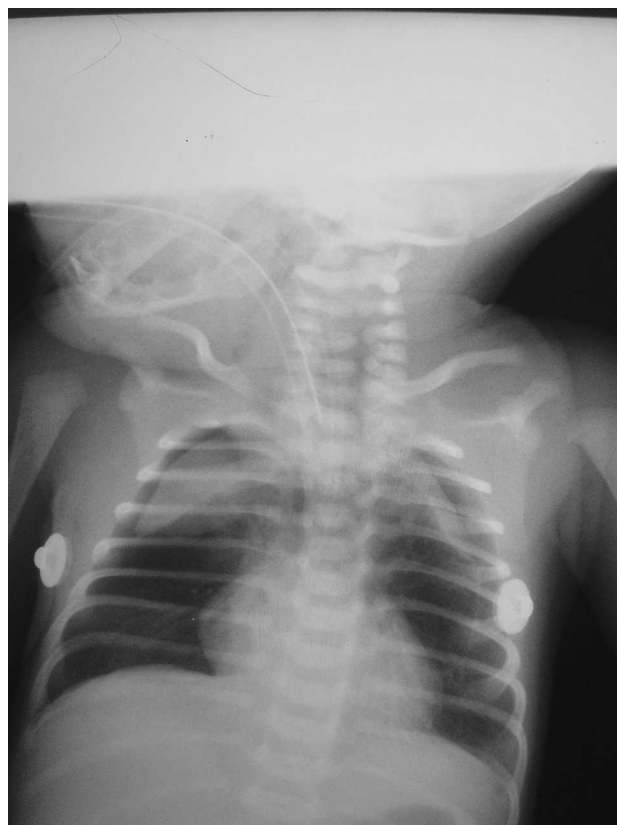


Figure 1 Plain chest radiograph.

The clinical quiz was prepared by:

MT **Soo**

Department of Paediatrics, Kwong Wah Hospital

SYR **LEE**

Department of Paediatrics and Adolescent Medicine, Princess Margaret Hospital

DKK **Ng**

Department of Paediatrics, Kwong Wah Hospital

Answer to "Clinical Quiz" on Page 384

N.B. The Editors invite contributions of illustrative clinical cases or materials to this section of the journal.